

ORIGINAL SCIENTIFIC PRESENTATION

Thigh Augmentation: Giving the Average Woman Curves in the Right Places

Nikolas V. Chugay, DO; Paul N. Chugay, MD

Introduction: *The curvaceous woman is in vogue again. Breasts are getting bigger, buttocks are getting fuller, and there is increasing demand for a fuller, more curvaceous look to the thighs. Some women have very slender thighs because of genetics or a vigorous exercise program. For those who have this problem, we have designed a solution: a custom implant that slides beneath the fascia lata and gives a bit more curve to the lateral thigh region.*

Materials and Methods: *A 3-cm incision is made in the transverse plane of the thigh, and dissection is carried down to the fascia lata. A pocket is created below the fascia using blunt dissection. Once the pocket is created, a custom-made lateral thigh prosthesis (AART Corp, Reno, Nev) is inserted into the subfascial plane. Closure is then performed in layers.*

Results: *To date, 18 patients have received lateral thigh prosthesis implantation. All patients were satisfied with the procedure and had no major complications associated with the procedure. One patient presented within 1 week of surgery complaining of some tightness in the area of the implant, raising the concern of compartment syndrome. The patient was observed and her symptoms resolved without further sequelae. No other complications or reoperations were noted in the study period.*

Conclusions: *This implant procedure helps the average woman achieve a fuller appearance in the thigh without significant risk or morbidity.*

In the days of antiquity, a curvaceous woman was a desirable commodity. A woman with curves was deemed fertile, having hips suitable for child bearing. Over time, the view of the woman changed and led to the belief that a slender woman, who was less shapely, was more attractive. Now, society has gained renewed interest in curvaceous women. A woman with a round bottom and curvy thighs has again become sexy and a

sign of true femininity. However, not everyone is born with these characteristics. Some women, particularly Asian women, are born with minimal development in the lateral thigh region. Also, some women who are extremely athletic have a very flat thigh area, despite having good tone and curve in other areas. To that purpose the authors continued in their efforts to improve form through muscle augmentation and created the thigh implant.

Materials and Methods

The prospectively collected data of 18 patients who had undergone thigh augmentation over the previous year were reviewed for postoperative complications and aesthetic results. All patients reviewed herein underwent the same procedure: insertion of a custom thigh implant (AART Corp, Reno, Nev) in a subfascial plane with meticulous hemostasis and closure in layers.

Procedure in Detail

A 3-cm incision is made in the high lateral aspect of the thigh in a transverse orientation, using a No. 15 Bard-Parker blade. Dissection through the subcutaneous tissues is performed using both blunt and sharp dissection down to the level of the fascia lata (Figure 1). Next, an incision is made in the fascia lata using a No. 15 blade. This incision is lengthened using Metzenbaum scissors, and 3-0 silk stay sutures are placed in the fascia lata on both sides. Dissection beneath the fascia is performed in a blunt fashion using a spatula dissector and a hockey-stick dissector.

Once the pocket has been completed, a custom Chugay lateral thigh prosthesis is placed into the subfascial plane (Figures 2 through 4). The fascia is then reapproximated and the subcutaneous tissues are brought together using 3-0 vicryl suture. The skin is

Received for publication March 11, 2011.

From the Chugay Cosmetic Surgery Institute, Long Beach, Calif.

Corresponding author: Nikolas V. Chugay, DO, Chugay Cosmetic Surgery Institute, 4210 Atlantic Ave, Long Beach, CA 90807 (e-mail: docchugay@hotmail.com).

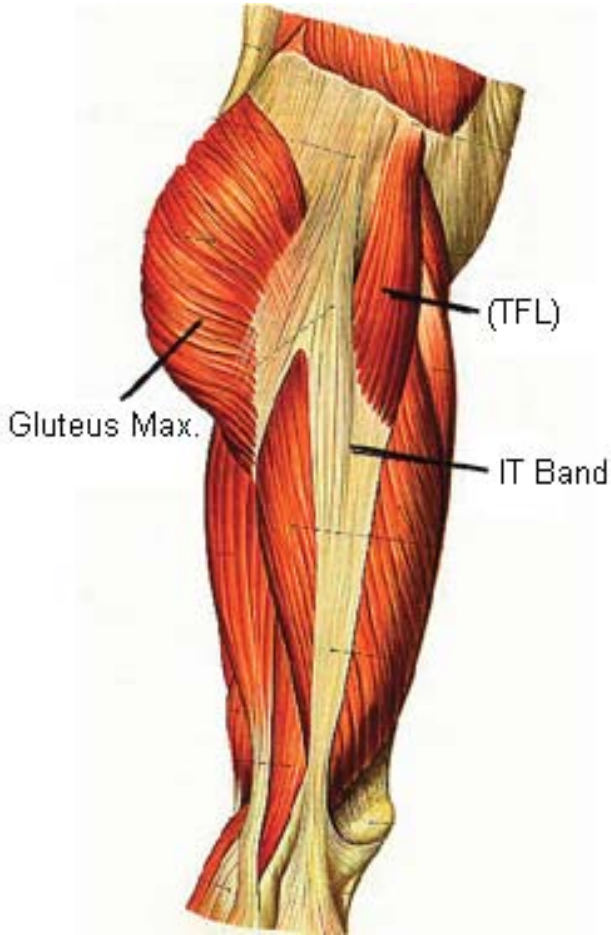


Figure 1. Anatomy of the lateral thigh with the tensor fascia lata (TFL) band noted. Incision is made through this band to allow for access of the implant.

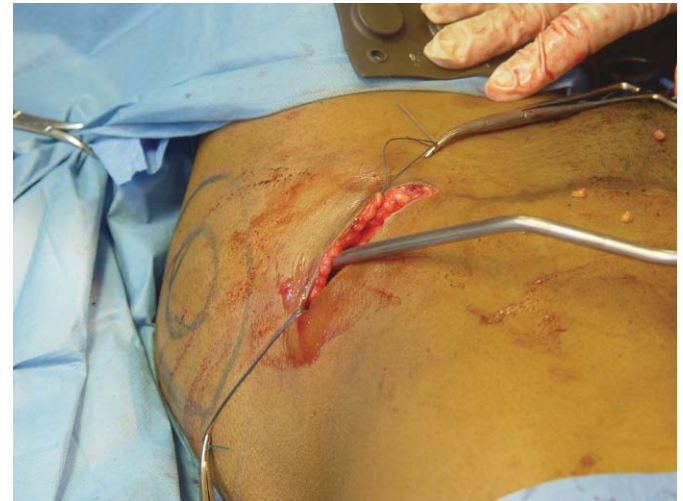

Figure 3. Plane of dissection of the pocket below the fascia lata. The left hip is shown with the lateral aspect of the thigh at 9 o'clock and the patient's feet at 12 o'clock. Stay sutures are noted in place, and the spatula dissector is entering at the 3:30 position.

then closed with 4-0 vicryl suture in subcuticular fashion. The patient is awakened from anesthesia and taken to the recovery room.

Postoperative Care

Postoperatively, the patient is placed into elastic compression garments to help minimize seroma formation in the lateral thigh region. These are to be worn 24 hours a day for a 4-week period. Patients are

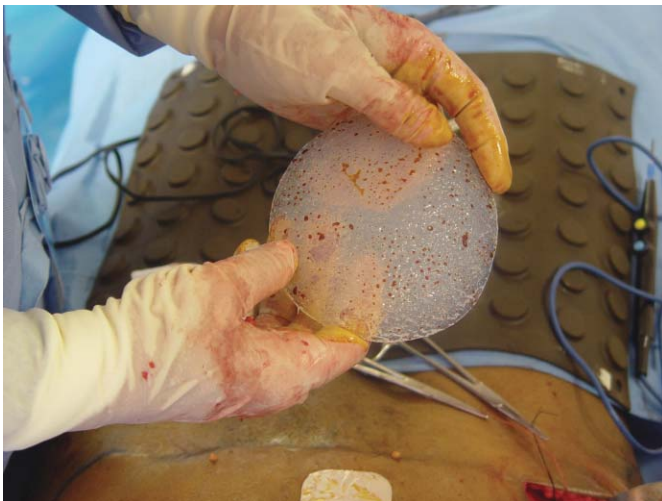

Figure 2. A medium thigh prosthesis before placement in a thigh augmentation procedure.

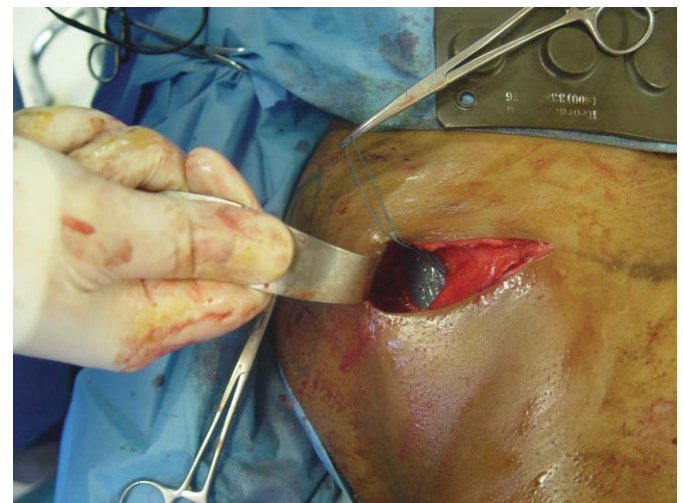
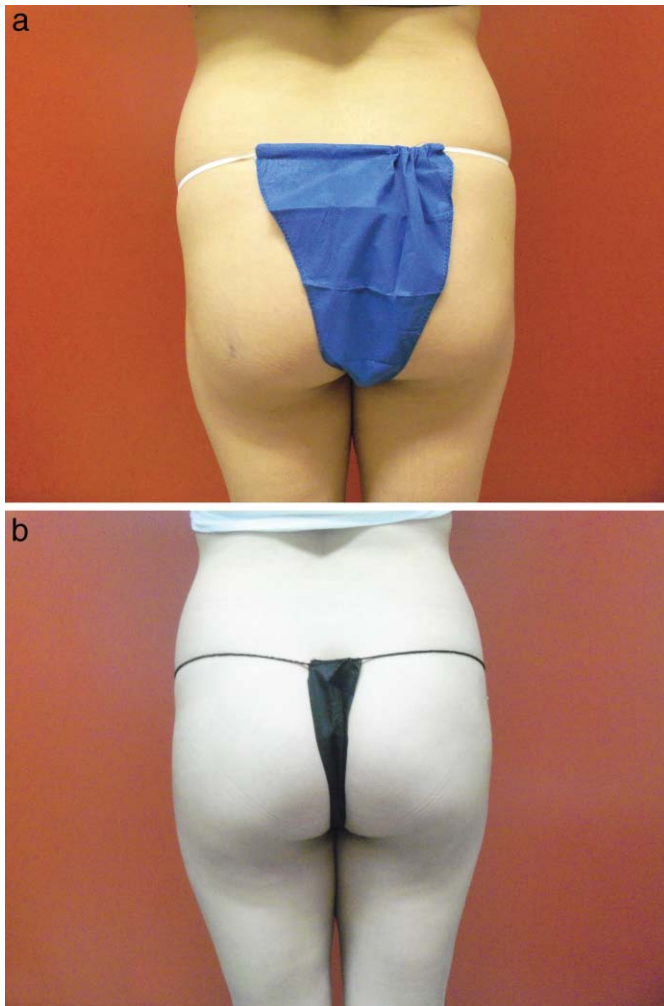


Figure 4. Thigh implant in position with the overlying fascia and stay sutures in the fascia. The patient's feet are at 12 o'clock, and the patient's left hip is depicted with the lateral aspect of the thigh at 9 o'clock.

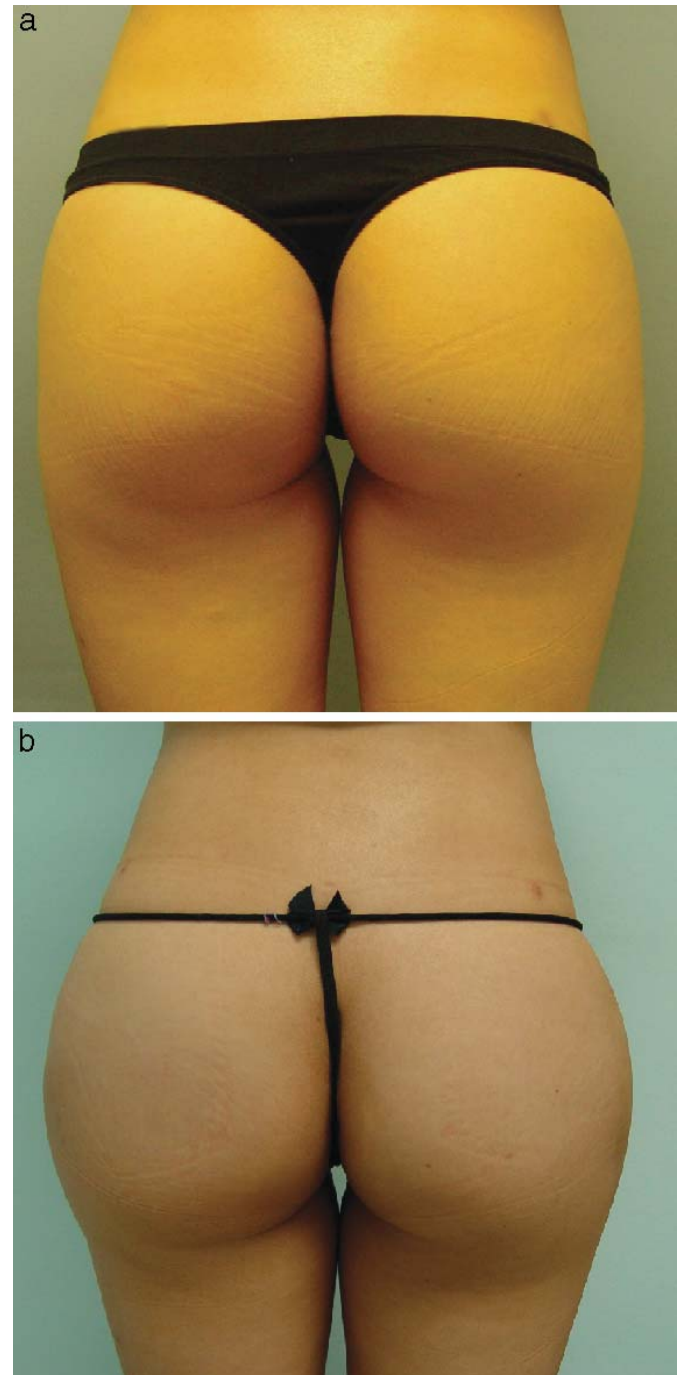


Figures 5. (a) Preoperative and (b) postoperative pictures of a patient (posterior view).

encouraged to resume light activity within 36–48 hours after surgery. Patients may return to light exercise within 2 weeks of surgery and vigorous exercise within 4–6 weeks.

Results

Since beginning the technique in late 2010, 18 patients have undergone the procedure (Figures 5 and 6). Depending on their physical dimensions and desire for more volume in the lateral thigh regions, 3 different types of implants were placed in the subfascial plane (small, medium, and large). Only 1 patient suffered a complication: suspicion of compartment syndrome. A 35-year-old woman presented within 1 week of surgery with complaints of tightness over the lateral thigh region on the right side. The skin was dusky and several vesicles were noted. Because of a lack of obvious signs of limb compromise,



Figures 6. (a) Preoperative and (b) postoperative pictures of a patient (posterior view).

observation with daily wound checks were performed. Within 4 days, the dusky skin improved and the vesicles disappeared. We believe the surgery was a success; however, the subfascial pocket was too tight for the size of the implant that was placed. Although it is important to maintain a snug fit around the implant to prevent migration, it has been our practice in

subsequent patients to perform a more generous pocket dissection to prevent this type of complication.

Discussion

The waist-to-hip ratio (WHR) is the ratio of the circumference of the waist to the circumference of the hips. In realm of general health, the WHR has been used as a measurement of obesity; those that have a higher index are typically more obese and have a greater potential for serious health conditions. Research shows that people with apple-shaped bodies (more weight around the waist) face more health risks than those with pear-shaped bodies (more weight around the hips). A WHR of 0.7 for women and 0.9 for men has been shown to correlate strongly with general health and fertility. Women within the 0.7 range have optimal levels of estrogen and are less susceptible to such major diseases as diabetes mellitus, cardiovascular disorders, and ovarian cancers.¹ The WHR has been found to be a more efficient predictor of mortality in older people than waist circumference or body mass index.²

Along with being a method of assessing general health, the WHR has long been used as a measure of attractiveness. Devandra Singh, an evolutionary psychologist at the University of Texas at Austin, has argued in multiple articles that the WHR is a significant measure of female attractiveness. Women who have a ratio near 0.7 are usually rated more attractive by men from European cultures.³ Icons of the silver screen such as Marilyn Monroe and Sophia Loren, long touted as pinnacles of beauty, had a WHR close to 0.7.³⁻⁵ Singh proposed a hypothesis to explain how WHR influences female attractiveness and its role in mate selection, citing evidence from studies of the WHR of Playboy playmates and Miss America winners over the past 30 years to support his work.⁴ In a 2010 article, Platek and Singh⁶ used functional magnetic resonance imaging to demonstrate that male participants looking at naked female bodies with an ideal WHR (approx 0.7) showed excitation in the anterior cingulate cortex, an area associated with reward processing and decision making. This further supports the premise that men appreciate curvy women and helps us understand the change in modern culture toward a more shapely and voluptuous woman.

Women have gone to great lengths in the past to alter their WHR. The corset was invented as a tool to reduce a woman's waist size to make her more physically attractive. Some women have resorted to

hip and buttock padding to increase the apparent size of the hips and buttocks. Female cosmetic patients routinely employ liposculpture to help redefine their waist area. Of late, buttock augmentation has been another means by which a woman can increase the curves in the lower pole of the body to help achieve a more aesthetically pleasing figure. The authors have developed a permanent solution for women who wish to increase their hip size to better suit the remainder of her figure and perhaps improve her level of attractiveness.

The placement of a lateral thigh prosthesis is not only facile but relatively safe. Because of the paucity of major structures in the lateral thigh region, the surgery can be performed with little fear of injuring a vital structure. After the incision through the skin is completed, the tensor fascia lata is exposed. It is through this band of fascia that the posterior branch of the lateral femoral cutaneous nerve arises. The lateral femoral cutaneous nerve of the thigh is a nerve of the lumbar plexus. This nerve bifurcates into anterior and posterior branches. The anterior branch becomes superficial about 10 cm below the inguinal ligament, and then it divides into branches that are distributed to the skin of the anterior and lateral parts of the thigh as far as the knee. The posterior branch pierces the fascia lata and supplies the skin from the level of the greater trochanter to the middle of the thigh posteriorly. Careful dissection of the fascia lata and use of blunt dissection below the fascia allows for the creation of a pocket with minimal risk of injury to the cutaneous nerves supplying the thigh region.

Potential complications of this procedure include, but are not limited, to the following: infection, seroma development, bleeding, implant extrusion, asymmetry, scarring, muscle damage, nerve damage (lateral femoral cutaneous), and compartment syndrome. However, because of the superficial position of the implant, the potential for injury to major structures is minimal.

Infection is minimized through the use of perioperative administration of antibiotics, bathing the implant in betadine before placement, and minimal handling of the implant by surgical staff. Seroma formation is prevented by using compressive garments for 4 weeks after surgery. In performing various muscle augmentation procedures, notably triceps and biceps augmentation, patients who were noncompliant with compressive dressings had a higher incidence of seroma formation requiring intervention. Bleeding is prevented by meticulous hemostasis throughout the procedure and avoidance of injury to the muscles of the thigh. Implant extrusion is prevented by performing

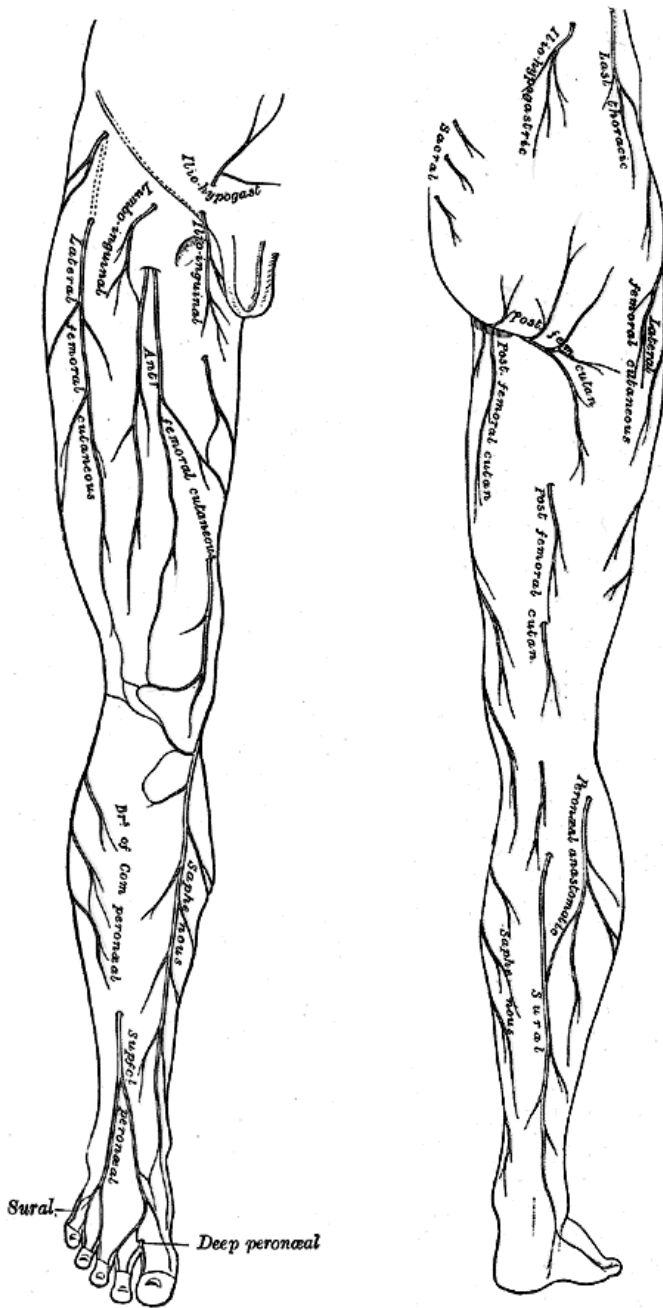


Figure 7. Anterior and posterior views of the lateral thigh region with the distribution of the lateral femoral cutaneous nerve (anterior and posterior branches).

an adequate dissection below the fascia lata, but at the same time allowing for a snug fit of the fascia around the implant. Scarring is minimized by closure in layers and avoidance of tension in the area overlying the implant. Nerve damage and muscle damage are minimized by using blunt rather than sharp dissection to create the pocket for the implant (Figures 7 and 8). By using tools such as the spatula dissector and hockey dissector along with blunt finger dissection, one is able

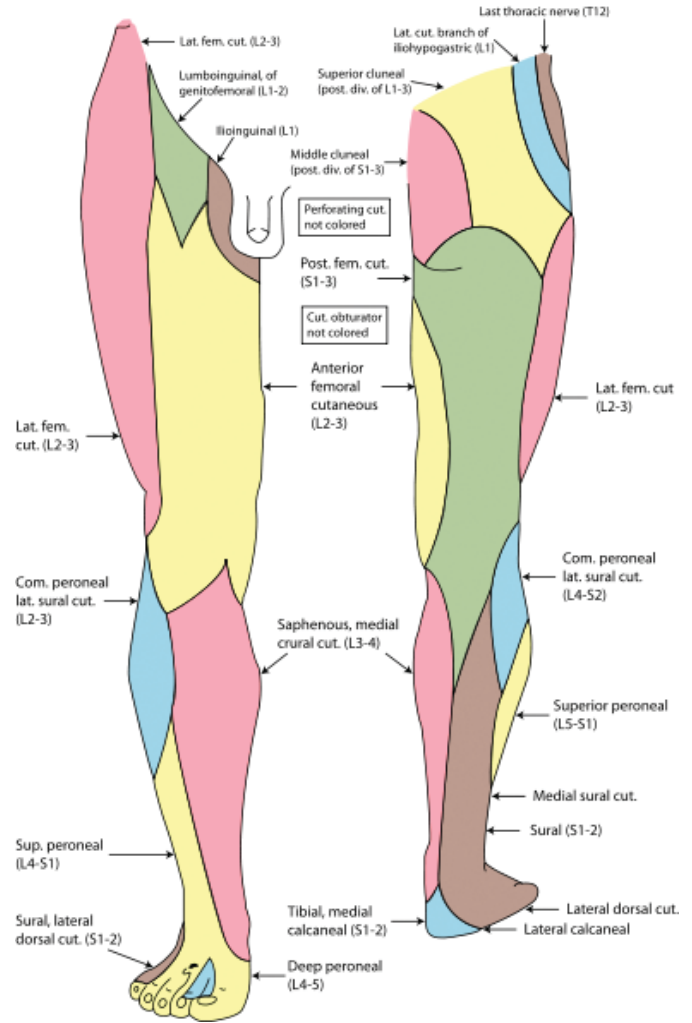


Figure 8. Sensory distribution of nerves of the thigh that may be affected with excessive traction or trauma to the lateral femoral region. Note must be taken of the areas of distribution of the posterior and anterior branches of the lateral femoral cutaneous nerves.

to avoid sharp dissection and inadvertent laceration of nerve structures in the operative field. Finally, compartment syndrome can be avoided with proper placement of implants that are not overly bulky and creating an adequately dissected pocket for the lateral thigh implant.

Conclusion

The curvaceous woman is back in vogue again. The demand for fuller, more curvaceous thighs has increased, and we have developed an implant to meet that need. Through a minimally invasive operation, women with minimal lateral thigh projection can be given a more curvy form to better mirror modern societal views of the eye-appealing feminine form.

References

1. Marlowe FW, Apicella CL, Reed D. Men's preferences for women's profile waist-hip-ratio in two societies. *Evol Hum Behav.* 2005;26:458–468.

2. Price GM, Uauy R, Breeze E, Bulpitt CJ, Fletcher AE. Weight, shape, and mortality risk in older persons: elevated waist-hip ratio, not high body mass index, is associated with a greater risk of death. *Am J Clin Nutr.* 2006;84:449–460.

3. Singh D, Young RK. Body weight, waist-to-hip ratio, breasts, and hips: role in judgments of female

attractiveness and desirability for relationships. *Ethol Sociobiol.* 2001;16:483–507.

4. Singh D. Adaptive significance of female physical attractiveness: role of waist-to-hip ratio. *J Pers Soc Psychol.* 1993;65:293–307.

5. Singh D. Body shape and women's attractiveness: the critical role of waist-to-hip ratio. *Hum Nat.* 1993;4:297–321.

6. Platek S, Singh D. Optimal waist-to-hip ratios in women activate neural reward centers in men. *PLoS One.* 2010;5(2):e9042. doi:10.1371/journal.pone.0009042.

THE AMERICAN SOCIETY OF COSMETIC BREAST SURGERY

Yearly Workshops on Breast Implant Surgery
& Cosmetic Breast surgery
The 28th annual workshop meeting is
Friday May 4th thru Monday May 7th, 2012 at
Newport Beach, California

A detailed program description, registration form,
And all information about the society is located
On the website: ascbs.org
CME credits for up to 28 hours may apply
Contact us by e-mail: ascbsweb@yahoo.com

Please note: The following four books by faculty members,
Melvin A. Shiffman, M.D., J.D. with contributions from our faculty
“Breast Augmentation: Principles and Practice”
“Mastopexy and Breast Reduction: Principles and Practice”
“Autologous Fat Transfer”
and “Anesthesia in Cosmetic Surgery” by Barry L. Friedberg, M.D.

ASCBS, 1419 Superior Ave., #2
Newport Beach, California 92663
Phone (949)645-6665 Fax (949)645-6784